

# MODULE 5 L08

# Lower Limb Blood Vessels

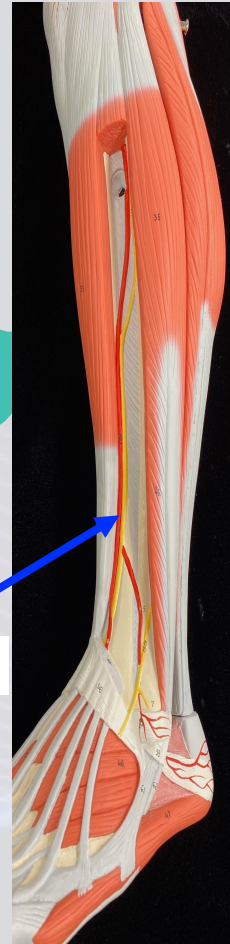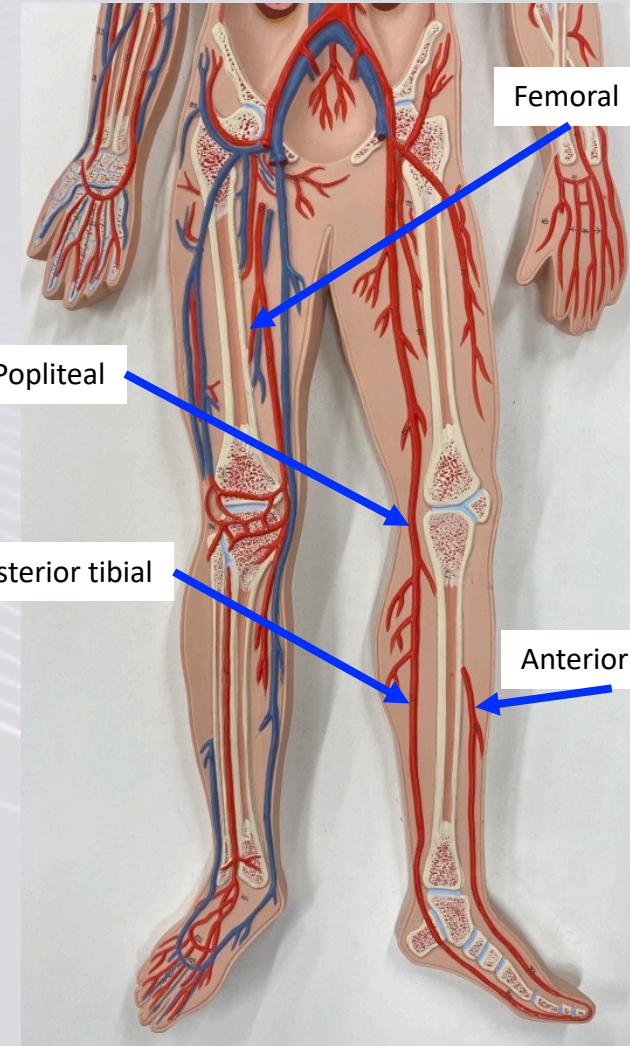
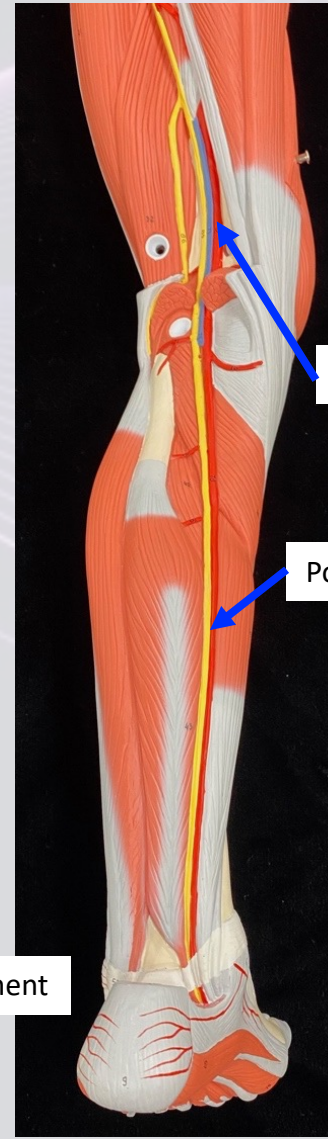
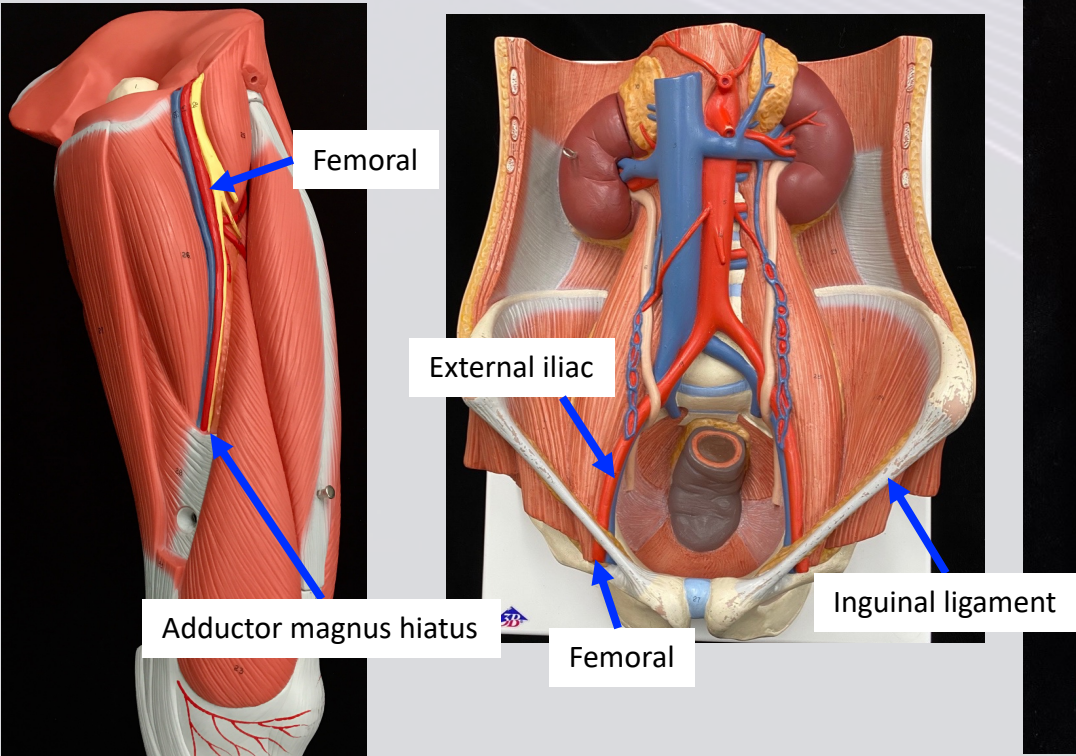
Dr. Lisa Brinn

[lbrinn@fiu.edu](mailto:lbrinn@fiu.edu)



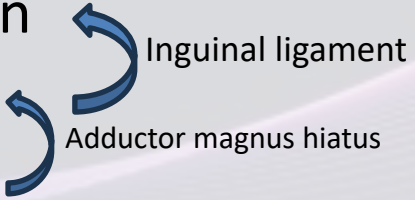
# F. Lower Limb Arteries

- External iliac artery
- Femoral artery
- Popliteal artery
  - ❖ Posterior tibial artery
  - ❖ Anterior tibial artery





# Lower Limb Veins

- External iliac vein
  - Femoral vein
  - Popliteal vein
- 
- The diagram shows two blue curved arrows. The top arrow points from the femoral vein towards the inguinal ligament. The bottom arrow points from the femoral vein towards the adductor magnus hiatus.
- Inguinal ligament
- Adductor magnus hiatus

Great saphenous veins – runs medial

